

medaxis

**EFFICACY OF WEEKLY DEBRIDEMENT
USING DEBRITOM+ MICRO WATER JET TECHNOLOGY ON
A NON-COMPLIANT PATIENT WITH AN INFECTED DFU
COMPLICATED BY COVID-19**



Audra R Siegel DPM, Christopher K Bromley DPM
Premier Medical Group, Poughkeepsie NY

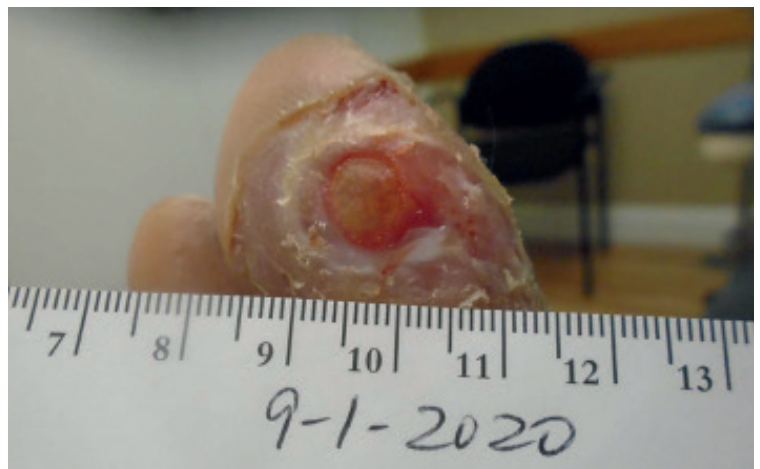debritom+
micro water jet debridement

Background

A 53-year-old male patient with a history of diabetes presented with nerve pain on the balls of his feet that had been present for 7 years and was steadily worsening. Patient experiences neuropathy and has a history of ulceration to the right second toe at the interspace. Wears ill-fitting sneakers and works on his feet all day. Day 0 revealed a single right hallux ulcer that grew in size and number over a period of 24 days. In this case study we explore how a new micro water jet debridement device called debritom⁺ can improve healing in a non-compliant patient.

Pre-debritom⁺ Assessment and Standard of Care Day 0

September 1, 2020: Patient presented with ulceration at the plantar hallux toe of the right foot measuring 0.8 cm x 0.8 cm. Granular tissue was present and serous drainage was observed. The surrounding area was hyperkeratotic, macerated, fibrotic and devitalized. Ulcer was debrided utilizing a #15 blade, a dressing applied, and a modified sneaker insert was used to offload. Patient received standard care (debridement, saline flush, Prisma, dry dressing) at least weekly for a month during which time the wound increased in size to 1.0 cm x 1.0 cm.

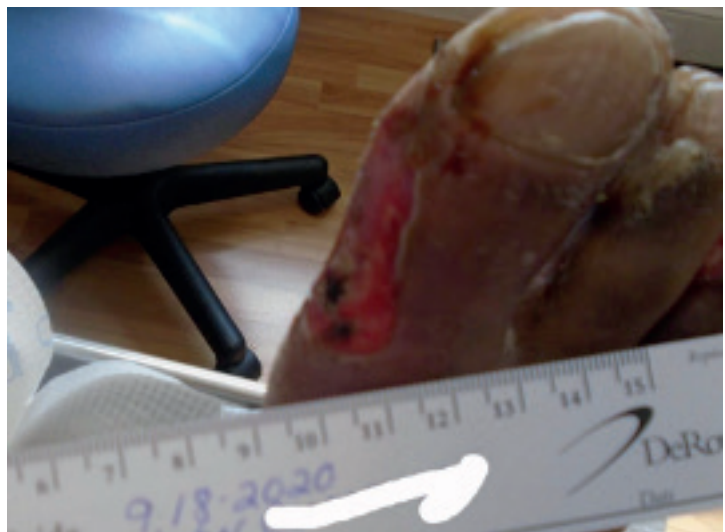
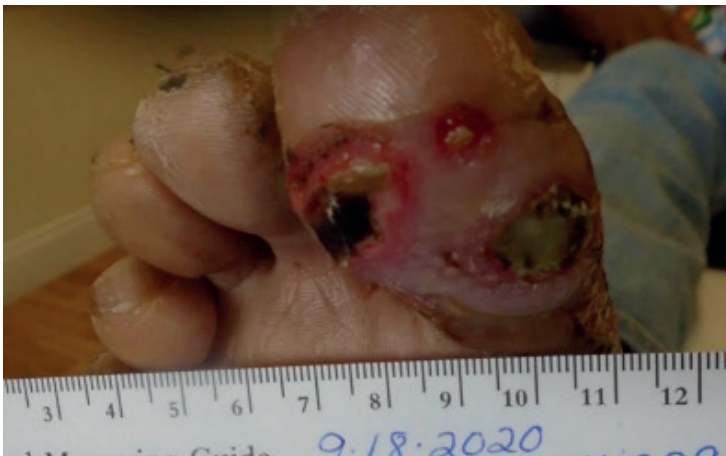
Day 14

Three distinct wounds now present:

1. Plantar interphalangeal joint of the right Hallux: Ulceration continued and X-rays showed there to be clear evidence of osteomyelitis. Incision and drainage was performed, with a moderate amount of purulent discharge evacuated. Swab cultures were taken.
2. Right hallux, extending from the prior ulceration to the dorsal medial aspect: Large bulla measuring 5.0 cm x 3.0 cm that extends through the skin. Granular tissue was absent and fibrous and necrotic tissues present. Drainage was moderate, serosanguinous, and purulent. Malodor was present and the surrounding area non-viable with slough. There was no probing to bone.
3. Medial aspect of the third toe of the right foot in the interdigital space: Edema and granular tissue were present, and drainage, fibrosis, necrotic tissue and malodor absent. The ulcer measured 0.3 cm x 0.3 cm x 0.1 cm.

Patient was prescribed oral antibiotics and standard of care. It was noted that the patient sneakers are too narrow for his foot, and has been instructed not to wear them, since they are most likely the cause of the breakdown/ulceration on the second and third toes due to pressure.



Debritom⁺ weekly debridement initiated on 5 ulcerations

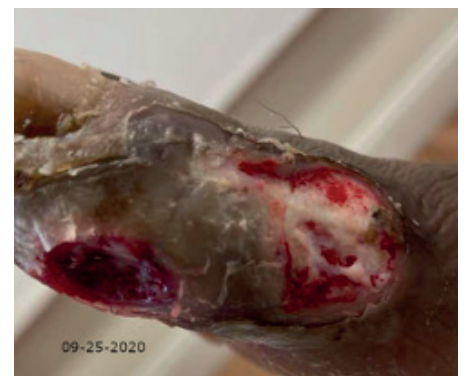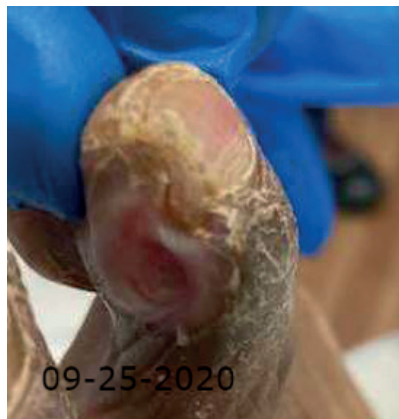
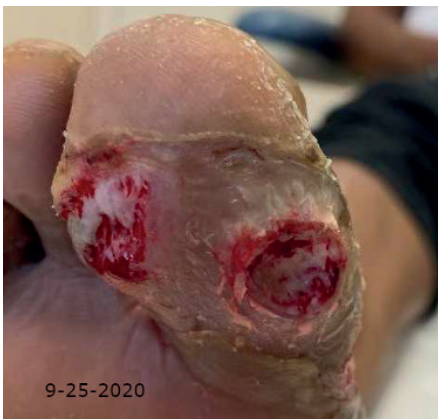Day 24 – debritom⁺ treatment #1

Patient is non-compliant with footwear recommendations, has resumed smoking, and been off work, however has continued antibiotic regimen (Bactrim DS and Cipro). Culture analysis confirmed heavy growth *Pseudomonas aeruginosa* as well as heavy growth *Serratia marcescens* (sensitive to Bactrim).

- 1) Ulceration observed at the Hallux, medial and proximal of the right foot. Measures 2.0 cm x 2.0 cm x 0.1 cm. Granular tissue present. Fibrous tissue present. Necrotic tissue present. Serous drainage observed. Surrounding area hyperkeratotic, macerated, and non-viable.
- 2) Ulceration observed on the plantar medial of the Hallux of the right foot. Measures 1.5 cm x 1.3 cm x 0.4 cm. Patches of necrotic tissue. Granular tissue present. Fibrous tissue positive. Serous drainage observed. Malodor present, foul-smelling. Surrounding area hyperkeratotic, macerated, and non-viable. No probing to bone.
- 3) Ulceration observed at the Hallux toe and lateral plantar of the right foot. Measuring 2.0 cm x 1.0 cm x 0.2 cm. Granular tissue present. Fibrous tissue positive. Necrotic tissue positive. Serous drainage observed. Surrounding area hyperkeratotic, macerated, and non-viable. Pseudomas odor.
- 4) Ulceration observed at the medial aspect of the third toe of the right foot in the interdigital space. Measures: 0.5 cm x 0.5 cm x 0.1 cm. Edema absent. Drainage absent. Granular base present. Fibrosis: absent. Necrotic tissue absent. Malodor absent.
- 5) Ulceration observed at the medial aspect of the second toe of the right foot in the interdigital space. Measures: 0.1 cm x 0.7 cm x 0.1 cm. Edema absent. Drainage absent. Granular base present. Fibrosis absent. Necrotic tissue absent. Malodor absent.

X-rays show sclerosis noted at proximal medial base of distal phalanx of hallux. No clear evidence of osteolysis is noted at this time to the right hallux.

Wounds debrided using debritom⁺ micro water jet technology. Acticoat 7 moistened with saline and dry dressing well-padded were applied. FF IPOS shoe dispensed to offload ulcers with instructions on ambulation. Recommended ATOI Topical Oxygen Therapy. Discussed smoking cessation.



Day 29 – standard of care only

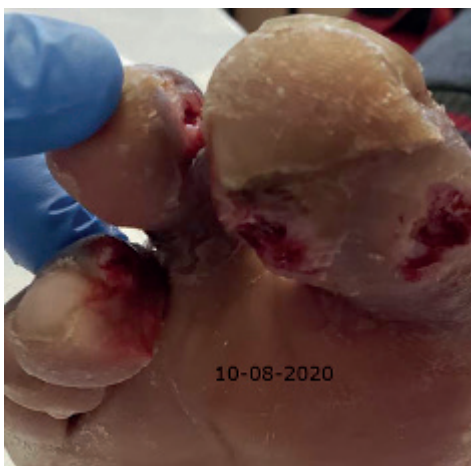Patient presents with dressing C/D/I. Finished Bactrim DS, and currently on Ciprofloxacin; he stated his foot feels better. Presented ambulating in prescribed IPOS forefoot offloading shoe. Wounds continue to decrease in size. Patient remains off work. Standard of care performed.

Day 37 – debritolom⁺ treatment #2

Patient presents with dressing C/D/I. Patient has been off work. Completed oral antibiotics. He stated his foot feels better. He presented ambulating in an IPOS forefoot offloading shoe and states that he has no pain other than the normal neuropathy. Malodor absent.

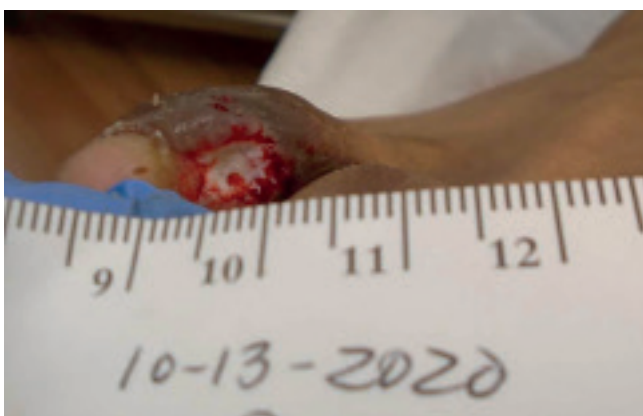
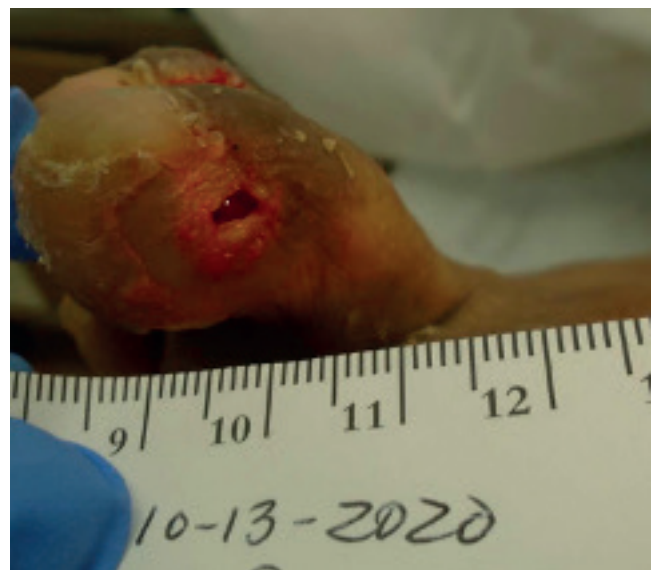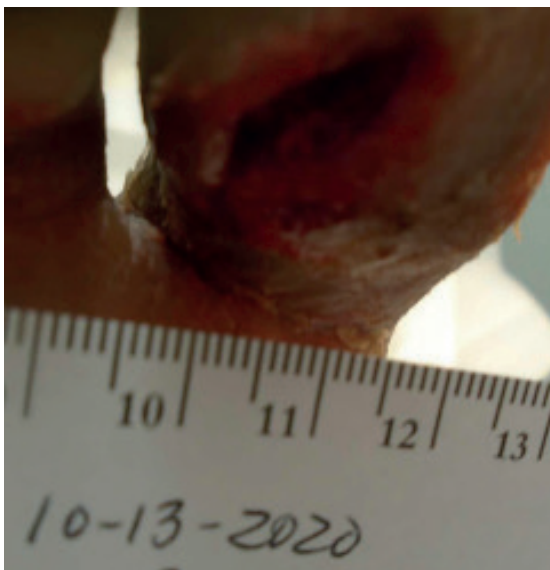
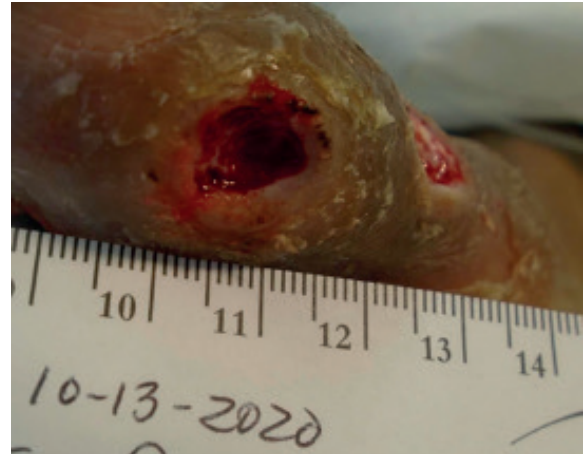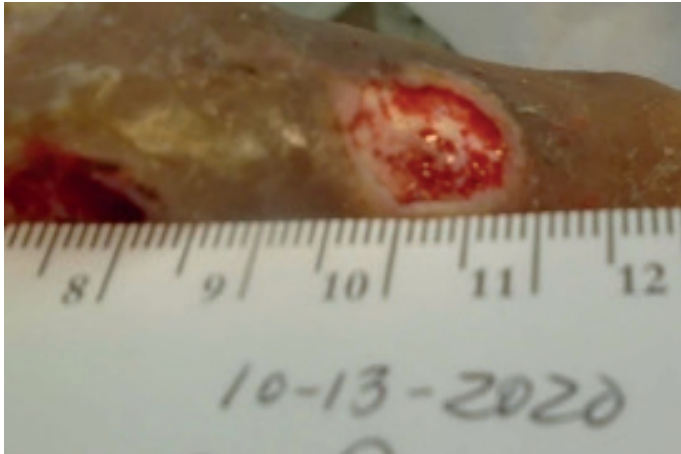
- 1) Ulceration on the plantar IPJ of the Hallux of the right foot reduced to 1.5 cm x 0.5 cm. Granular tissue present. Fibrous tissue positive. Necrotic tissue absent. Serosanguenous drainage observed. Hyperkeratotic surrounding skin.
- 2) Ulceration on the dorsal medial aspect of the Hallux toe of the right foot. Measures 1.0 cm x 1.5 cm. Granular tissue present. Fibrous tissue positive. Necrotic tissue absent. Serous drainage observed. Hyperkeratotic surrounding skin.
- 3) Ulceration observed on the plantar medial aspect of the Hallux toe of the right foot. Measures 1.5 cm x 1.0 cm. Granular tissue absent. Fibrous tissue positive. Necrotic tissue present. Serous drainage observed. Surrounding area non-viable and hyperkeratotic.
- 4) Ulceration at the medial aspect of the third toe of the right foot in the interdigital space. Measuring 1.0 cm x 0.5 cm. Edema present. Drainage absent. Granular base present. Fibrosis absent. Necrotic tissue absent.
- 5) Ulceration at the medial aspect of the second toe of the right foot in the interdigital space. Measuring 0.4 cm x 0.4 cm. Edema present. Drainage absent. Granular base present. Fibrosis absent. Necrotic tissue absent.

The ulcers were all debrided utilizing debritolom⁺ micro water jet technology. Prisma and dry dressing well-padded were applied. Continue to ambulate in FF IPOS shoe to offload ulcers with instructions on ambulation.



Day 42 – debritolom+ treatment #3

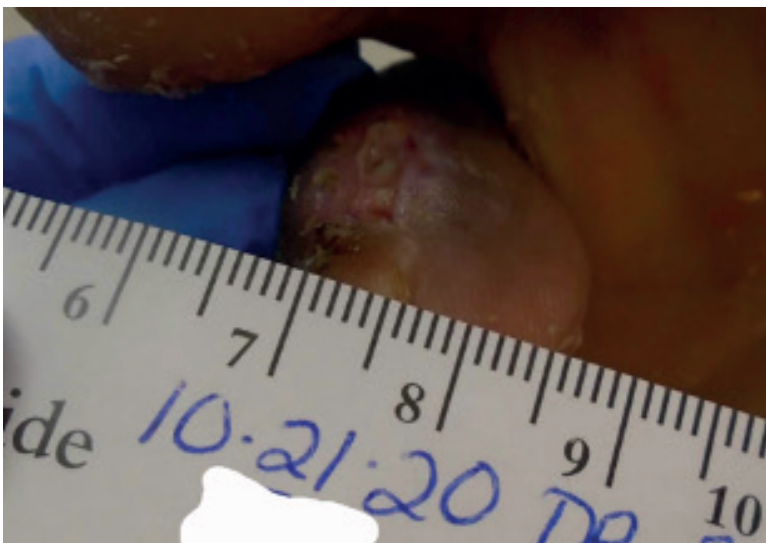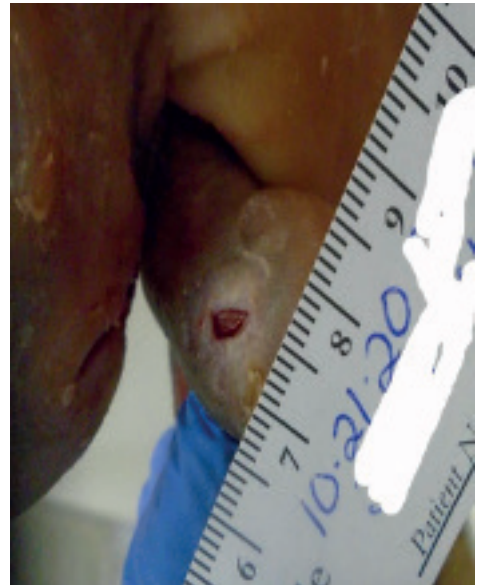
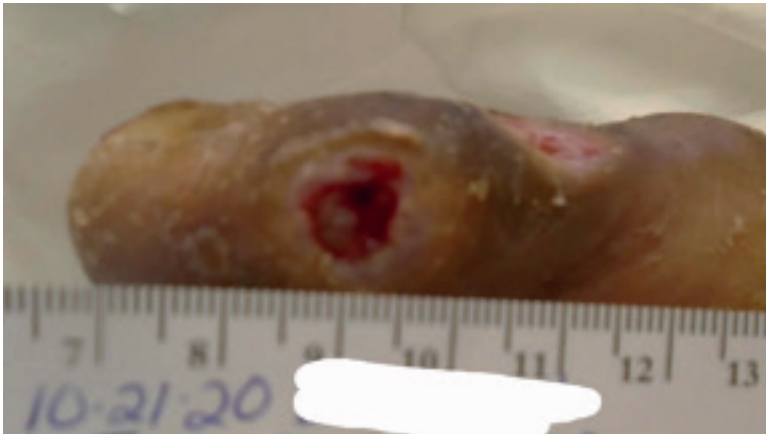
Granulation progress in plantar IPJ right Hallux and dorsal medial Hallux. Periwound skin WNL, no malodor, some drainage and necrotic tissue. Debrided all wounds using debritolom+ micro water jet technology followed by Actico-at 7 dressing. Continue to wear FF IPOS shoe.



Day 50 – debritolom⁺ treatment #4

Patient observed walking inappropriately (toes hitting the ground). Instructed on proper use of FF IPOS shoe. Free of pain and malodor. Some draining. Compliant with topical O₂ therapy. Has missed one appointment.

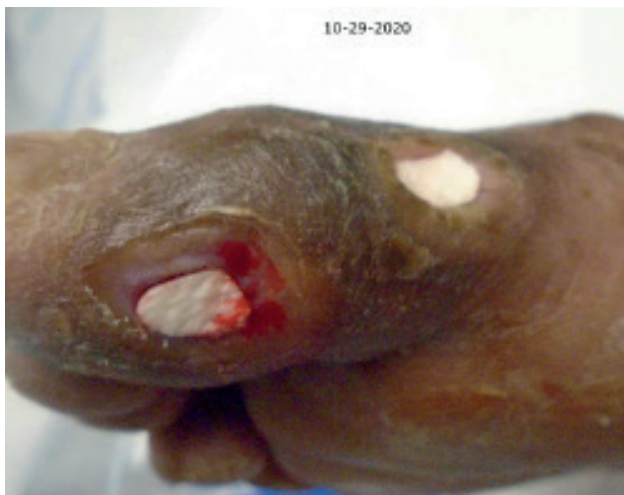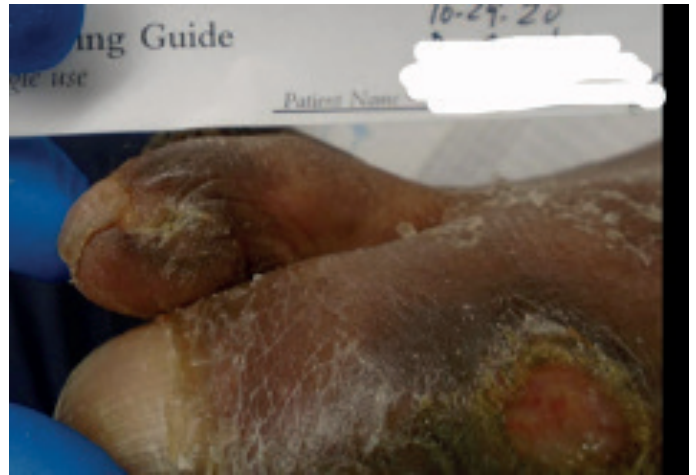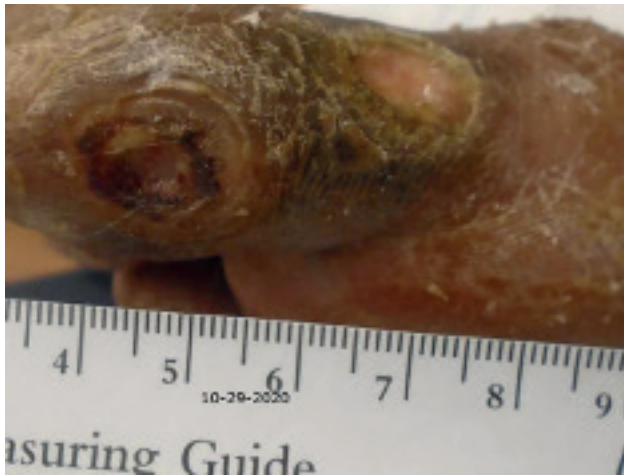All ulcers were all debrided utilizing a debritolom⁺ micro water jet technology. Acticoat 7 moistened with saline and dry dressing well-padded were applied. Patient was instructed to continue to ambulate in FF IPOS shoe to offload ulcers and re-instructed on proper ambulation. ATOI Topical Oxygen Therapy was continued.



Day 58 – debritolom⁺ treatment #5

Dressing strikethrough indicates that the patient's been ambulating without the FF IPOS shoe and has been re-educated that ambulating without shoe prevents healing. Continues topical O₂ therapy. Four of the five wounds show granulation tissue and no necrosis. Periwound skin WNL.

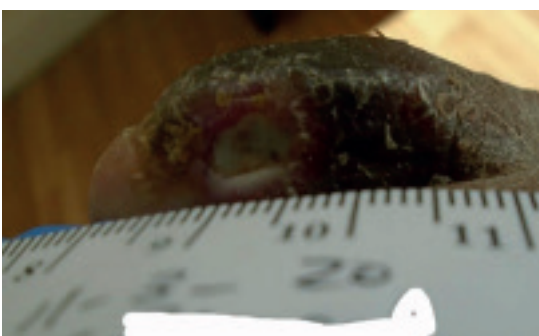
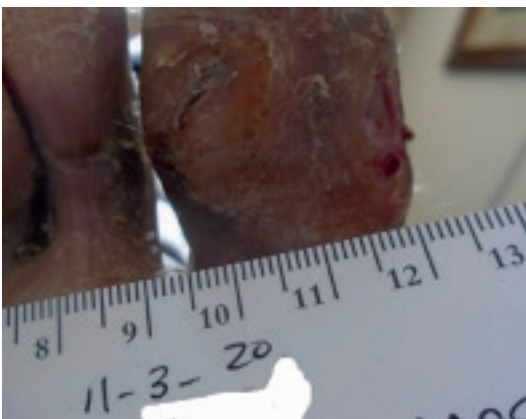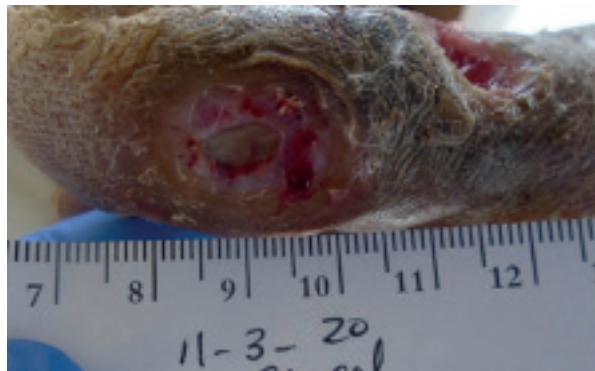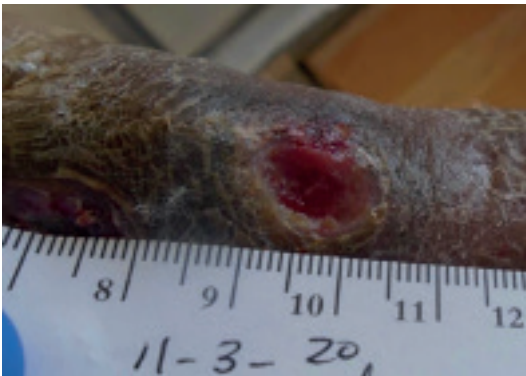Debridement with debritolom⁺ micro water jet technology. Placed Kerecis graft on wound post-debridement and covered with Surgex dressing.



Day 63 – Standard of Care

Primary right IPJ hallux ulcer presented on Day 0 has resolved. Standard of care resumed on remaining ulcers.

- 1) Ulceration observed on the plantar IPJ of the Hallux of the right foot. Measures 0 cm. Wound resolved!
- 2) Ulceration observed on the dorsal medial aspect of the Hallux toe of the right foot. Measures 1.9 cm x 0.9 cm x 0.3 cm. Base: Ulceration extends fully through skin. Granular tissue present. Fibrous tissue absent. Necrotic tissue absent. Serous drainage observed. Surrounding skin hyperkeratotic, epibole. Malodor absent. No probing to bone.
- 3) Ulceration observed on the plantar medial aspect of the Hallux toe of the right foot. Measures 0.9 cm x 0.5 cm x 0.3 cm. Granular tissue absent. Fibrous tissue positive. Necrotic tissue present. Drainage: serous drainage observed. Malodor absent. Surrounding area hyperkeratotic, epibole. No probing to bone.
- 4) There is an ulceration at the medial aspect of the third toe of the right foot in the interdigital space. Measures 0.9 cm x 0.6 cm x 0.2 cm. Edema absent. Drainage serous. Granular base present. Fibrosis present. Necrotic tissue: absent. Malodor: absent.
- 5) There is an ulceration at the medial aspect of the second toe of the right foot in the interdigital space. Measures 0.4 cm x 0.2 cm x 0.2 cm. Edema absent. Drainage none. Granular base present. Fibrosis absent. Necrotic tissue absent. Malodor absent.



Day 75

Patient admitted to hospital with Covid-19 diagnosis. Wound consult conducted.

- 1) Small ulceration remaining at the medial aspect of the 2nd toe distally. Ulceration measures approximately 0.3 x 0.3 x 0.1 cm. It has a beefy red granulation base. No edema erythema increased warmth or drainage indicate lysed infection.
- 2) Ulceration over the medial aspect of the right hallux measuring approximately 1 cm x 0.5 cm x 0.1 cm. There is a thin overlaying layer of skin appears stable but fragile. No drainage is noted. No edema erythema increased warmth or drainage to indicate localized infection.
- 3) The previously present ulceration on the 3rd toe has apparently healed.
- 4) Ulcerations to patient's 2nd right toe appears virtually healed ulceration noted to patient's 1st right toe also feels virtually healed. Recommend every other day application of dry sterile dressing between the toes and about the foot. No other treatment is necessary these ulcerations should go on to heal uneventfully over the next few days.

Discussion

A large challenge in any wound care practice is resolving hard-to-heal DFUs with patients who are non-compliant with nearly every instruction: offloading, smoking, dressing changes, office visits, etc.

A complete wound debridement is fundamental to jump starting the healing process. debritolom⁺ micro water jet technology can be used in the office to eliminate non-viable tissue and biofilm, allowing the wound to advance from the inflammatory stage to the granulation stage. The procedure is fast and well-tolerated, providing a proper microbleed for excellent wound bed preparation. In many cases, it may help avoid admission to hospital for surgical debridement.

In this case study, prior to debritolom⁺ use, a single hallux ulcer quickly increased in size and number over a period of 24 days with evidence of osteomyelitis. Wound culture revealed *Pseudomonas aeruginosa* and *Serratia marcescens*.

A weekly series of five micro water jet debridements, along with oral antibiotics, an off-loading shoe, AWC dressings, topical O₂ and attentive medical care allowed the wounds to resolve or significantly reduce in size. To this end, the use of debritolom⁺ was highly effective in healing or reducing wound size and severity in this non-compliant patient, who had responded poorly to standard of care treatment.

During this pandemic, it is impossible to predict "the rest of the story". The patient in this case study was admitted to hospital with COVID-19 and succumbed to the virus. In many patients it is uncertain whether a setback such as COVID-19 or major hospitalization will undo all or part of the progress made in a patient's wound healing. And so, the challenge continues.....