

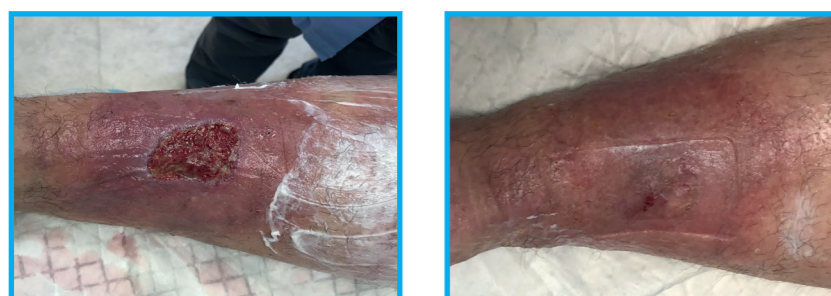# Efficacy of Micro-Water-Jet Debridement of Acute & Chronic Wounds in an Office-Based Setting

Charles K Lee MD FACS<sup>1,2</sup>, Tina Lin RN<sup>1</sup>, Nakyung Kim MD<sup>1</sup>, Gina Restani ORT<sup>1</sup>

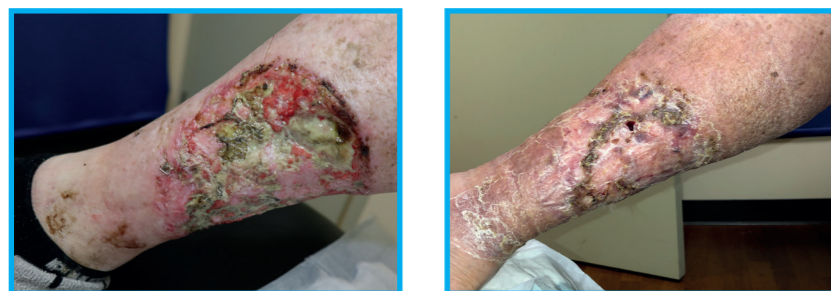<sup>1</sup>L plastic surgery, San Francisco; <sup>2</sup>University of California-San Francisco (UCSF)

## Introduction

Debridement is a critical step in wound bed preparation and healing. Multiple debridement tools exist with their associated advantages and disadvantages. We evaluate the clinical efficacy and ease-of-use of Micro Water Jet debridement (MWJ) on acute and chronic wounds in an office-based setting.



Male, 50yo patient. Wagner grade I VLU wound to right leg (8x8cm). Single debridement resulted in healing in 2 weeks. Images show before, and healed wound 2 weeks post-debridement.



Male, 68yo patient. Wagner grade I basal cell cancer wound to right leg (10x10cm). Dual debridement followed by skin graft resulted in healing in 2 weeks. Images show before first debridement and healed wound 2 weeks post-treatment.

## Methods

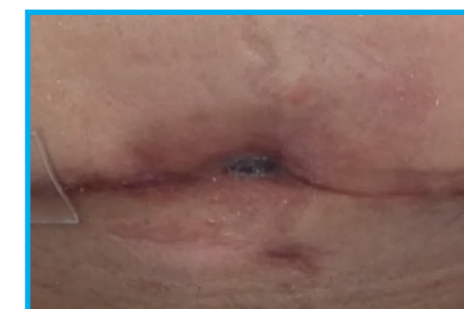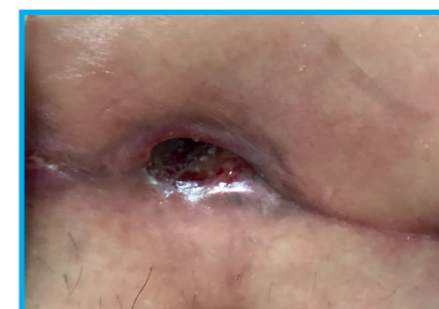
A series of 4 patients were evaluated with different wound types, location, and size who underwent micro-water-jet-debridement with saline. Average wound size was 35 sq. cm (Range: 25sq cm - 100 sq. cm). Clinical efficacy was noted by punctate bleeding and removal of desired tissue, with follow-up to document healing status. Ease-of-use was evaluated by set up time, surgeon's evaluation of the micro-water-jet's debridement characteristics, and patient comfort.



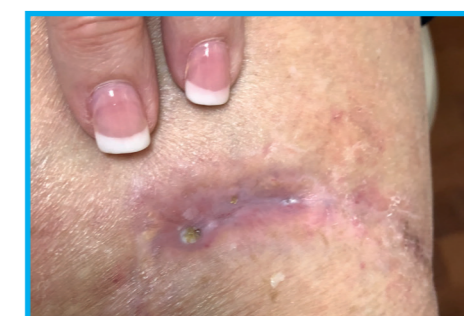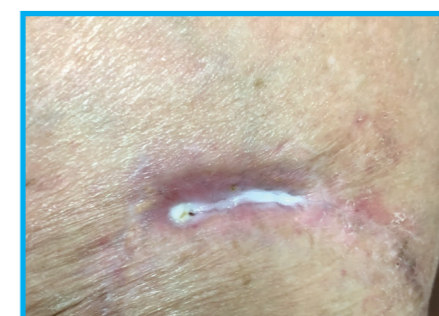The debritor+ Micro Water Jet debridement technology by medaxis, [www.medaxis.us](http://www.medaxis.us)

## Results

All four patients underwent successful debridement using the micro-water-jet debridement in the office. Punctate bleeding and effective removal of tissue were noted in all patients. All patients healed or had documented wound healing by decreased dimensions during an 8-week follow-up. Setup time was straightforward (Average 7 minutes, Range 5-10 minutes) and the surgeon described the debridement as precise and efficient with minimal patient discomfort. There were no adverse events with bleeding or infection.



Female, 35yo patient. Wagner grade I abdominal wound (5x5cm). Single debridement resulted in healing in 6 weeks. Images show before and 4 weeks post-debridement.



Female, 74yo patient. Wagner grade I wound to right leg (5x5cm). Two debridements resulted in healing in 4 weeks. Images show before and immediately after debridement.

## Conclusion & Discussion

Micro Water Jet (MWJ) debridement is a clinically efficacious and simple system for debridement of acute and chronic wounds in the office setting. Patients tolerated this form of debridement well with minimal discomfort and achieved healed wounds with adjunctive local wound care. MWJ debridement in the office setting has many advantages over traditional forms of debridement (scalpel, curette, radical surgical) while avoiding the costs of an operating room. Future studies should include a more global economic cost analysis of using this device in the outpatient and inpatient setting, and in conjunction with various biologics with MWJ wound bed preparation.